

Case Report

Metastatic cervical lymphadenopathy masquerading as extrapulmonary tuberculosis

Adebolajo A Adeyemo

Abstract:

Introduction: Cervical lymphadenopathy can be due to various pathologies especially in the young. A high index of suspicion is required in the management of cervical lymphadenopathy to prevent misdiagnosis and wrong treatment.

Case report: Here present the diagnostic challenge in the case of a young lady with nasopharyngeal carcinoma who initially presented solely with cervical lymphadenopathy. Previous fine needle aspiration cytology had suggested tuberculosis (TB) and she was commenced on anti-TB drugs. However failure of improvement and worsening symptoms led to another review in ENT clinic. A subsequent nasopharyngeal biopsy confirmed nasopharyngeal carcinoma. She subsequently improved after commencement of appropriate treatment.

Conclusion: In regions with a high prevalence rate of tuberculosis, care must be taken to exclude malignancy in patients with cervical lymphadenopathy even when cytology suggests a granulomatous infection.

Key words: Nasopharyngeal carcinoma; tuberculosis; cervical lymphadenopathy; metastatic

Introduction:

Tuberculosis (TB) has been resurging in the past few decades, with about 9 million new cases diagnosed annually¹. A number of factors including Acquired Immuno-deficiency Syndrome (AIDS) pandemic have been attributed to this surge in the incidence of TB². Extra pulmonary TB presentations have also been on the increase³⁻⁴ and cervical lymphadenopathy is reported to be the commonest form of this presentation³⁻⁵. However there are many possible differential

diagnosis of a clinical presentation of cervical lymphadenopathy. In the younger age groups inflammatory lesions and malignant neoplasm are commoner than benign neoplasm and non-inflammatory benign lesions⁶. Nasopharyngeal cancer (NPC) is one of the malignant neoplasm of the head and neck region may present solely with cervical lymph node enlargement. Originally described in 1921, NPC is the commonest epithelial malignancy in adults⁷⁻⁹. Among paediatric age groups it accounts for a third of all nasopharyngeal cancers¹⁰. Since the many causes of cervical lymphadenopathy may mimic each other especially in a setting with a high burden of infectious diseases this may lead to delayed accurate diagnosis and/or commencement of unnecessary treatment.

Institute of Child Health, University of Ibadan, Nigeria.

Address of Correspondence: Adebolajo A Adeyemo MBBS, MSc, FWACS, Institute of Child Health, University of Ibadan, PMB 5017, Nigeria. Phone: +2348037172329, Email: adebolajo@hotmail.com

The paper presents the diagnostic challenge in the case of a young lady with nasopharyngeal carcinoma who initially presented with solely cervical lymphadenopathy.

Case report:

A twenty-year-old female student presented to the General outpatient clinic with a 3 month history of a progressive right cervical swelling. A series of investigations were ordered, the results are outlined:

ESR: 68mm/hour, WBC: 5,800/mm³, Neutrophils-66%, lymphocytes-29%, monocytes-3%, Eosinophils-2%, PCV- 39%, Mantoux test: 12mm x11mm, FNAC: Chronic granulomatous inflammation.

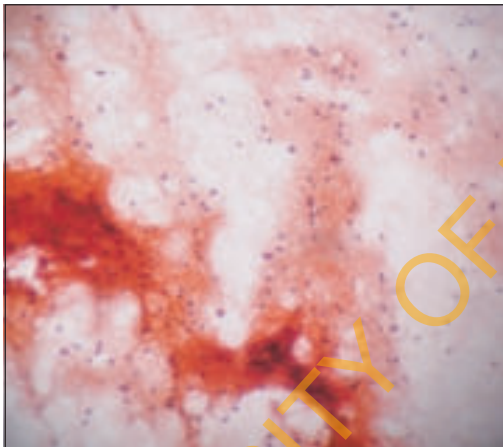


Figure 1: Cytology smear of the cervical lymph node.

She defaulted from the clinic but returned seven months later when she noticed a left cervical swelling. She was referred to Medical outpatient clinic with a diagnosis of tuberculous lymphadenitis based on the investigation results especially the cytology report. A similar diagnosis was made in the medical clinic based on the investigation results and she was commenced on anti-TB drugs (INH, Rifampicin, Ethambutol, and Pyrazinamide). However after two months of

using the anti-TB drugs she made complaints of recurrent purulent nasal discharge which is occasionally blood stained and partial loss of hearing in the right ear and was referred to Ear, Nose and Throat (ENT) clinic on account of the nasal discharge and hearing loss.

Further review in ENT yielded additional history of snoring, mouth breathing, spontaneous recurrent epistaxis and right side otalgia. There was also history of difficulty in mouth opening and dysphagia, weight loss and occasional fever but no night sweats. Examination in the ENT clinic revealed a mouth breathing patient with muffled voice. Rinne's test was negative on the right. There was a fleshy mass in the left nasal cavity with purulent discharge and downward depression of the soft palate on the right. There were multiple bilateral cervical lymph nodes; the largest node on the right was 12cm x 8cm, and on the left 4cm x 4cm.

A diagnosis of nasopharyngeal tumour was made with a differential diagnosis of right sinonasal tumour. An examination under anaesthesia of the nasopharynx and nasal cavities was planned. Operation findings were: fleshy friable mass with contact bleeding on the right side of the nasopharynx extending into the right nasal cavity. Histology report was undifferentiated nasopharyngeal carcinoma.

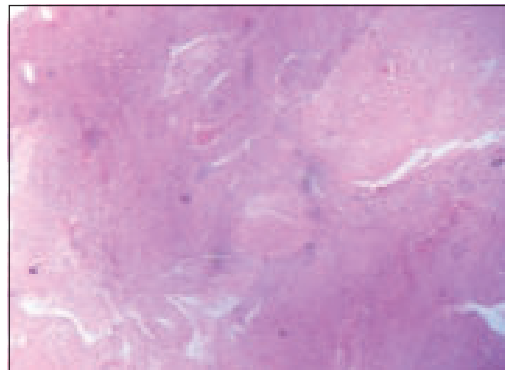


Figure 2: Section from the nasopharyngeal biopsy.

She was offered chemo- and radiation therapy with discontinuation of anti-TB drugs. She had 6 courses of Cisplatin and 5-Fluorouracil and 50 Gy of radiation to the facio-cervical region bilaterally. All the symptoms were obliterated at the end of the therapy, the left cervical nodes became non-palpable and the only node palpable on the right was 2cm x 3cm. There were no significant complaints at follow-up clinic until she was lost to follow up.

Discussion:

A high index of suspicion is required when managing young patients with cervical lymphadenopathy in regions with high prevalence of chronic granulomatous infection. As initially thought by the family physician and the pulmonologist the cervical lymphadenopathy seen in this patient could have been due to the TB-the similarity of presentation between TB and NPC have been noted¹¹, however other factors that may suggest a different diagnosis exist in this patient.

Nasopharyngeal carcinoma has a bimodal peak age of presentation and the younger age peak is seen in the second decade of life⁷⁻¹². The age of the patient presented falls within the younger age peak for NPC which suggests that NPC could have been responsible for the cervical lymphadenopathy.

Cervical lymphadenopathy is the commonest presentation of NPC¹³; hence a differential diagnosis of NPC should be entertained especially when the lymphadenopathy is bilateral and painless. The nasopharynx being a midline structure implies that malignant lesions of the region tend to metastasize to both sides of the neck. The bilateral nature of the lymphadenopathy in this patient highly suggests NPC.

A controversy exists on the sensitivity of FNAC for cervical tuberculous adenitis. While some authors have reported sensitive rates as high

as 90% others have reported rates as low as 46%⁵⁻¹⁴. Although some authorities have advocated that the occurrence of granulomatous features on FNAC is highly suggestive of TB in developing countries, where TB is common¹⁵ this suggested approach must be taken with great caution as this case has demonstrated. Diagnosing TB based on cytological findings of epithelioid cell granulomas and multinucleated giant cells with or without caseous necrosis⁵ may be misleading as similar features are present in metastatic NPC. The presence of epithelioid granulomas has been clearly demonstrated in the cytology of metastatic cervical lymph node secondary to a primary NPC^{11, 16}.

The family physicians and the pulmonologist based their diagnosis on the FNAC and possibly the ESR results leading to a delay of 3 months before commencement of anti-cancer therapy. This delay could be fatal in other circumstances, to forestall such a delay it may be necessary to order Ziehl-Neelsen staining of the cytological smear to confirm diagnosis in suspicious cases¹⁷ or EBNA (Epstein Barr virus Nuclear Antigen) immunocytochemistry¹⁸.

Even though physicians often face a challenge between the resources of the patients and ordering extensive investigations to aid diagnosis, especially in developing countries where a significant portion of health related bills are out-of-pocket expenses for the patients, maintaining a high index of suspicion might prevent unnecessary delay in accurate diagnosis as exemplified in this case.

References:

1. Harries AD, Dye C. Tuberculosis. *Ann Trop Med Parasitol* 2006; 100(5-6): 415-31.
2. Miziara ID. Tuberculosis affecting the oral cavity in Brazilian HIV-infected

- patients. *Oral Surg Med Pathol Radiol Endod* 2005; 100: 179–82.
3. Elder NC. Extrapulmonary tuberculosis: A review. *Arch Fam Med* 1992; 1: 91-8.
 4. Mert A, Tabak F, Ozaras R, Tahan V, Ozturk R, Aktuglu Y. Tuberculous lymphadenopathy in adults: a review of 35 cases. *Acta Chir Belg* 2002; 102: 118–21.
 5. Khan R, Harris SH, Verma AK, Syed A. Cervical lymphadenopathy: scrofula revisited. *J Laryngol Otol* 2009; 123(7): 764-7. Epub 2008/10/11.
 6. Ayugi J, Ogengo J, Macharia I, Olabu B. Pattern of acquired neck masses in a Kenyan paediatric population. *Int J Oral Maxillofac Surg* 2011; 40(4): 384-7. Epub 2010/12/07.
 7. Brennan B. Nasopharyngeal carcinoma. *Orphanet Journal of Rare Diseases* 2006; 1(23).
 8. Regaud C. Lympho-épithéliome de l'hypopharynx traité par la roentgenthérapie. *Bull Soc Franc Otorhinolaryngol* 1921; 34: 209-14.
 9. Schmincke A. Über lymphoepitheliale Geschwülste. *Beitr Pathol Anat* 1921; 68: 161-70.
 10. Young JLJ, Miller RW. Incidence of malignant tumors in U. S. children. *J Pediatr* 1975; 86: 254-8.
 11. Chan ABW, Ma TKF, Yu BKH, King AD, Ho FNY, Tse GMK. Nasopharyngeal granulomatous inflammation and tuberculosis complicating undifferentiated carcinoma. *Otolaryngol Head Neck Surg* 2004; 130: 125-30.
 12. Balakrishnan U. An additional younger-age peak for cancer of the nasopharynx. *Int J Cancer* 1975; 15: 651-7.
 13. Easton JM, Levine PH, Hyams VJ. Nasopharyngeal carcinoma in the United States: a pathologic study of 177 US and 30 foreign cases. *Arch Otolaryngol* 1980; 106: 88–91.
 14. Nemish ZA, Mah MW, Mahmood SA, Bannatyne RM, Khan MY. Clinico-diagnostic experience with tuberculous lymphadenitis in Saudi Arabia. *Clin Microbiol Infect* 2000; 6: 137–41.
 15. Lau SK, Wei WI, Hsu C, Engzell UC. Efficacy of fine needle aspiration cytology in the diagnosis of tuberculous cervical lymphadenopathy. *J Laryngol Otol* 1990; 104: 24–7.
 16. Kollur SM, El Hag ID. Fine-Needle aspiration cytology of metastatic nasopharyngeal carcinoma in cervical lymph nodes: comparison with metastatic squamous-cell carcinoma, and Hodgkin's and Non-Hodgkin's Lymphoma. *Diagn Cytopathol* 2002; 28(1): 18-22.
 17. Mittal P, Handa U, Mohan H, Gupta V. Comparative evaluation of fine needle aspiration cytology, culture, and PCR in diagnosis of tuberculous lymphadenitis. *Diagn Cytopathol* 2011; 39(11): 822-6. Epub 2011/10/14.
 18. Chang MKM, McGuire LJ, Lee JCK. Fine needle aspiration cytodiagnosis of nasopharyngeal carcinoma in cervical lymph nodes. A study of 40 cases. *Acta Cytol* 1989; 33: 344–50.